

CASE REPORT

# Cerebellar haemorrhage mimicking acute peripheral vestibulopathy: the role of the video head impulse test in differential diagnosis

## *Vertigine centrale "maligna" secondaria ad emorragia cerebellare: ruolo del video head impulse test nella diagnosi differenziale*

E. ARMATO, E. FERRI, A. PINZANI<sup>1</sup>, E. ULMER<sup>2</sup>

Department of Otorhinolaryngology, Hospitals of Mirano and Dolo (Venice), Italy; <sup>1</sup> Department of Radiology, Hospital of Dolo (Venice), Italy; <sup>2</sup> ENT Consultant, Neuro-Otological Office, Cannes, France

### SUMMARY

Dizziness and vertigo without neurological signs are typically due to a peripheral vestibular disease. Although the most common causes are benign, differential diagnosis must include potentially life-threatening central diseases such as cerebrovascular pathologies. A systemic clinical approach needs a careful work-up, bedside examination and appropriate instrumental investigation. The head impulse test (HIT) allows qualitative clinical assessment of canal function; it has some limitations such as subjective evaluation, mainly in patients with a spontaneous nystagmus. A new device has been recently developed consisting of an infrared video camera (video-HIT) to provide quantitative instrumental assessment of the high-frequency vestibular-ocular reflex (VOR) gain. By reporting a case of cerebellar haemorrhage mimicking an acute peripheral vestibulopathy, the authors suggest that video-HIT may be considered a useful tool in differential diagnosis between vestibular neuritis and cerebellar vascular disease in patients with severe acute vertigo without central signs.

KEY WORDS: Cerebellar haemorrhage • Central vertigo • Peripheral vertigo • Vestibular neuritis • Head impulse test

### RIASSUNTO

*Una sindrome vertiginosa non associata a segni clinici neurologici è più comunemente riferibile ad una patologia vestibolare periferica. Anche se le cause più comuni sono benigne, la diagnosi differenziale deve includere le malattie centrali potenzialmente letali come quelle cerebrovascolari. Un approccio sistemico necessita di un'attenta anamnesi, di un esame clinico e di un'appropriate indagine strumentale. Il test impulsivo rotatorio o head impulse test (HIT) permette una valutazione qualitativa clinica della funzione canalare ma presenta alcuni limiti legati soprattutto alla valutazione soggettiva, specialmente in pazienti con nistagmo spontaneo. Un nuovo dispositivo, che utilizza una telecamera ad infrarossi video (video-HIT), è stato sviluppato di recente per fornire una valutazione quantitativa strumentale del guadagno del riflesso vestibulo-oculare (VOR) ad alta frequenza. Descrivendo il caso clinico di un'emorragia cerebellare che potrebbe simulare una vestibulopatia periferica acuta, gli autori dimostrano che il video-HIT può essere uno strumento molto utile nella diagnosi differenziale tra neurite vestibolare e malattia vascolare cerebellare in pazienti con vertigine severa acuta senza segni centrali.*

PAROLE CHIAVE: Emorragia cerebellare • Vertigine centrale • Vertigine periferica • Neurite vestibolare • Videotest impulsivo rotatorio

Acta Otorhinolaryngol Ital:EPUB February 09, 2012

## Introduction

Acute dizziness and vertigo are a common problem in patients presenting to the emergency room, as well as for otolaryngologists and neurologists. It is important to recognize potentially serious causes of acute vertigo or dizziness (cerebrovascular ischaemia, stroke, cerebellar infarction and/or haemorrhage), since these may require specific and prompt treatment. The rate of cerebrovascular events in patients with acute dizziness and vertigo is very low (3.2%), and when these symptoms are not associated with any other neurological signs or symptoms, cerebrovascular disease is diagnosed in only 0.7% of patients<sup>1</sup>.

Although dizziness, vertigo and imbalance in isolation are a strong indicator of peripheral disease, recent studies have reported contradictory findings. They have suggested that isolated episodic vertigo can only be the manifestation of cerebrovascular disease (transient ischaemia, stroke or haemorrhage)<sup>2-6</sup>. Approximately 10% of patients with cerebellar infarction complain of vertigo and have no localizing neurologic deficits<sup>7</sup>.

There are luckily a variety of clues in physical examination that can allow differentiation between central and peripheral causes of acute vertigo or dizziness. For instance, where there are other associated neurologic signs (e.g. cra-

nial nerve findings, hemiparesis, facial weakness, diplopia, hyperesthesia and Horner's sign), central causes of vertigo should be immediately suspected. Central disorders can produce a nystagmus that presents one or more of these features: a) it changes direction with gaze (gaze-evoked nystagmus); b) it is not modified by visual fixation; c) its directional components are pure vertical or torsional.

Misdiagnosis of a central lesion can lead to serious consequences. Many evaluation centres routinely perform brain imaging for patients presenting a new-onset acute vertigo, even in the absence of either definitive or suggestive central signs. Although brain imaging will rarely uncover a structural abnormality, the method is accurate and is the only means of ruling out a life-threatening disorder<sup>8</sup>.

Many otolaryngologists and neurologists include a clinical test in daily practice which allows evaluation of peripheral vestibular function, namely the head impulse test (HIT). Described in 1988 by Curthoys and Halmagyi<sup>9</sup>, it determines the individual response of each of the six semi-circular canals. A new device endowed with an infrared video camera (video-HIT) has been recently developed in the attempt to resolve dubious HIT results. Video-HIT may be useful in a patient with a severe acute vertigo without central signs for an adequate differential diagnosis between vestibular neuritis when it is usually positive, and cerebellar vascular disease when it is usually negative<sup>10,11</sup>.

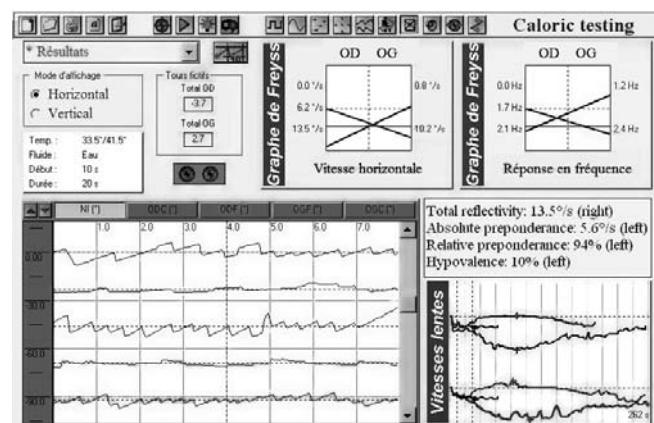
A vestibular system can physiologically detect small changes of head position and rapidly adjust eye movements allowing the patient's vision to remain centred on the target. When the head of patients with acute vestibulopathy is turned toward the affected side, there will be a delay in vestibular adjustment. Such a delay will manifest as a brief and fixed gaze toward the affected side followed by a corrective saccadic eye movement back to the target<sup>12</sup>. Video-HIT is a suitable tool to improve diagnostic accuracy and to determine if the bedside positive HIT is actually caused by reduced VOR gain or if it simply results from clinical misjudgement<sup>11</sup>.

The aim of this report is to advocate a possible role of video-HIT as an easy, quick and useful test in vestibular assessment and differential diagnosis of central disease mimicking peripheral vertigo.

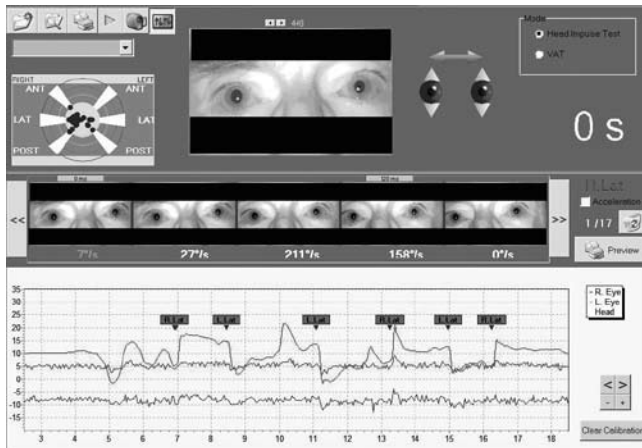
## Case report

A 74-year-old male presented to our emergency room with a history of acute sudden vertigo with nausea and vomiting, which has been present for three days; there were no headache, dysarthria, limb ataxia, difficulty in walking and/or other central signs or symptoms. One month prior, he had suffered three other episodes of transient, acute, sudden vertigo lasting a few minutes. The patient was under treatment for systemic hypertension. ECG has shown previously undiagnosed paroxysmal atrial fibrillation. He had third degree, spontaneous, station-

ary, pure horizontal left-beating nystagmus, not modified by changing head positions and not inhibited by visual fixation. The head shaking test did not modify the spontaneous nystagmus. Vestibulospinal testing was normal. Saccadic eye movements did not demonstrate abnormalities of accuracy or velocity. Smooth pursuit was slightly impaired: the rightward gain was 0.80 and the leftward was 0.70. There was no gaze-evoked nystagmus when looking rightward as it always remained left-beating. The patient was admitted to the ENT department. Caloric testing showed a leftward directional preponderance (absolute preponderance, 5.6°/sec; relative preponderance, 94%) without significant hypovalence (10% on the right side) (Fig. 1). Pure tone audiometry revealed a symmetrical bilateral sensorineural loss with prevalent involvement of high frequencies (2-8 kHz). Video-HIT analysis was performed using a device (video-head impulse Test 2.0, Synapsys, France) composed of a high resolution and high light sensitivity video camera that is located in front of the patient's face at a distance of about 80 cm; it is linked to a computer for automatic image analysis. The operator can confirm a positive test by a simple observation on the videoculocephaloscope (HIT scope) and record the image for later reference. Using this device, eye movements can be recorded for analysis and quantify the deficit of each semi-circular canal<sup>13</sup>. A specific algorithm calculates the real-time speed of head movement and direction. If acceleration conditions required by the Halmagyi test are not satisfied, the software does not measure a VOR deficit. When the correct threshold of acceleration is reached, the software calculates gaze deviation compared to head rotation. This comparison is made between two images: the first image at the beginning of the head thrust, and the second image at the end of the rotation, before the voluntary refixation saccade. In our patient, video-HIT did not show abnormal values on either side, revealing normal function of the six semi-

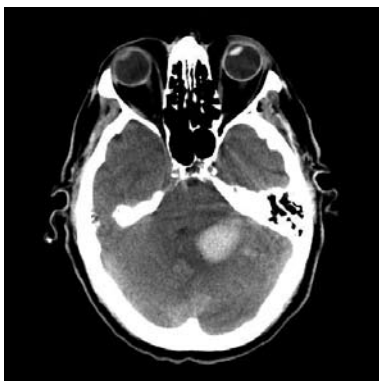

**Fig. 1.** Bithermal caloric testing shows a leftward directional preponderance (absolute preponderance, 5.6°/sec; relative preponderance, 94%) without significant hypovalence (10% on the right side).

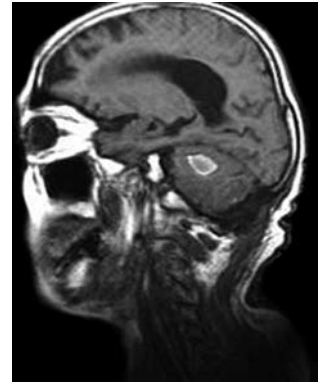

**Fig. 2.** Video-HIT shows normal function of the six semi-circular canals. The semi-circular canals are displayed as a six branch star called the “canalogram”. Displayed in the top-left corner of the screen, it expresses the percentage of canal paresis. Branch orientation is in relation to canal anatomical array. The canalogram represents the patient facing the examiner, and therefore the left branch of the canalogram are on the patient’s right SCC. The green zone of the canalogram is the statistically normal zone. The dots identify the results of measurement of the head impulse test. The position of the dot indicates that the canal deficit is within normal limits (values: from 0% to 35% for the lateral canal and from 0% to 40% for vertical ones) or pathological. The operator stimulates a specific canal, and the results will be immediately displayed if the tested canal is damaged and indicate to what proportion. The canalogram displays the results of involvement by a single canal or multiple canals.

circular canals. The canalogram, displayed in the top-left corner of the screen, quantified the percentage of canal paresis (normal values: from 0% to 35% for the lateral canal and from 0% to 40% for the vertical ones) (Fig. 2). Because of the negativity in video-HIT, the directional preponderance, the persistence of vertigo with nausea and a slight headache, the disease was likely to have had a central cause. A cerebral computed tomography (CT) demonstrated a left anterior-inferior cerebellar haemorrhage that was deforming the brainstem and the fourth ventricle to the opposite side (Fig. 3). Diffusion-weighted brain magnetic resonance imaging (MRI) confirmed cerebellar vascular disease (Fig. 4). The patient was immediately transferred to the Neurosurgery Unit and underwent surgical posterior craniotomy. A follow-up MRI showed no further



**Fig. 3.** Axial image of cerebral non-contrast CT shows a left anterior-inferior cerebellar haematoma in the parafloccular region, measuring about 2.5 cm in its largest diameter, with a mild “mass effect”, brainstem distortion and shift of the fourth ventricle to the contralateral side.



**Fig. 4.** T1-weighted sagittal image of brain MRI shows a cerebellar haematoma with a hemosiderin ring suggesting subacute haemorrhage.

progression of cerebellar haemorrhage. Six-months later, the patient was well, without any neurologic deficits.

## Discussion

The interpretation of HIT results requires careful clinical observation of eye/head synchronism, although such synchronism is often difficult to confirm due to the very short duration of the phenomenon. It is reported that between 9% and 39% of positive clinical HIT have been falsely described in patients with genuine acute cerebellar or brainstem strokes, and thus the presence of a subjective sign cannot be solely relied upon to identify a benign pathology<sup>14,15</sup>. Some authors have recently stated that a negative HIT is found in 91% to 96% of patients with cerebellar infarction<sup>7,15,16</sup>. Therefore, all clinical features (e.g. directionality of nystagmus, severity of truncal instability, nature of hearing loss) must be considered in patients with acute vestibular syndrome<sup>14,17</sup>. HIT is a clinical sign and presents some limitations such as subjective evaluation, different accelerations and velocities during rotation of the head, absence of objective measure of VOR (Vestibular-Ocular Reflex) gain, difficulty in detecting the “overt” saccade and impossibility in detecting the “covert” one<sup>11</sup>. In order to resolve these problems and to avoid dubious HIT results, a new medical device (video-HIT) based on a standalone video camera recording patient’s face has been developed. The software analyzes both patient gaze and head rotation. The device guarantees correct test performance (i.e. with head acceleration enough to abolish optokinetic reflex participation) and quantification of VOR gain. The scleral search coil technique has been the gold standard for HIT measurements, quantifying the VOR deficit in vestibular diseases. However, search coil measurements require the subject to wear an uncomfortable contact lens, are time intensive, expensive and are not practical in an acute setting. The simultaneous video and search coil HIT recordings validate the diagnostic accuracy of video-HIT. Despite different recording methods, many authors have described that head and eye velocity recordings are closely comparable, and mean VOR gains measured with search coil and video are not significantly different in normal subjects and patients with vestibular disease<sup>11,19-21</sup>.

Video-HIT is both sensitive and specific to detect unilateral hypofunction of the peripheral vestibular system, which is commonly caused by acute vestibulopathy<sup>13,18</sup>. The video-HIT is simple and fast, appears likely to separately assess the six semi-circular canals and as it is performed under physiological conditions is comfortable for the patient. It evaluates the vestibular capacities of response only to high frequencies, and independently of the result does not replace caloric tests within the framework of a complete examination. Nonetheless, it is an excellent test under the conditions of the current patient case, and is also essential in complete examination of vestibular function.

Video-HIT is most useful in patients with acute vertigo, where it helps to distinguish peripheral vestibular loss (positive test) from a central vestibular lesion (negative test). If the test appears to be negative, the clinician will suspect acute cerebellar vascular disease and will order imaging tests. When neuroimaging is indicated, CT and MRI are both excellent studies for haemorrhagic strokes<sup>22</sup>.

## Conclusions

The most widespread vestibular disorders seen by otolaryngologists are benign paroxysmal positional vertigo and vestibular neuritis. However, some life-threatening brainstem or cerebellar strokes can mimic these diseases. Additional clinical features (e.g., directionality of nystagmus or severity of truncal instability) must be considered. In a patient with acute vestibular syndrome without neurologic signs or symptoms, a negative video-HIT appears to be useful in diagnosis of central disease.

## References

- 1 Kerber KA, Brown DL, Lisabeth LD, et al. *Stroke among patients with dizziness, vertigo, and imbalance in the emergency department: a population-based study*. Stroke 2006;37:2484-7.
- 2 Huang CY, Yu YL. *Small cerebellar stroke may mimic labyrinthine lesions*. J Neurol Neurosurg Psychiatry 1985;48:263-5.
- 3 Gomez CR, Cruz-Flores S, Malkoff MD, et al. *Isolated vertigo as a manifestation of vertebrobasilar ischemia*. Neurology 1996;47:94-7.
- 4 Lee H, Cho YW. *A case of isolated nodulus infarction presenting as a vestibular neuritis*. J Neurol Sci 2004;221:117-9.
- 5 Kim HA, Lee SR, Lee H. *Acute peripheral vestibular syndrome of a vascular cause*. J Neurol Sci 2007;254:99-101.
- 6 Lee H. *Neuro-otological aspects of cerebellar stroke syndrome*. J Clin Neurol 2009;5:65-73.
- 7 Nelson JA, Virre E. *The clinical differentiation of cerebellar infarction from common vertigo syndromes*. West J Emerg Med 2009;10:273-7.
- 8 Fiebach JB, Schellinger PD, Gass A, et al. *Stroke magnetic resonance imaging is accurate in hyperacute intracerebral hemorrhage: a multicenter study on the validity of stroke imaging*. Stroke 2004;35:502-6.
- 9 Halmagyi GM, Curthoys IS. *A clinical sign of canal paresis*. Arch Neurol 1988;45:737-9.
- 10 Black RA, Halmagyi GM, Thurtell MJ, et al. *The active head-impulse test in unilateral peripheral vestibulopathy*. Arch Neurol 2005;62:290-3.
- 11 MacDougall HG, Weber KP, McGarvie LA, et al. *The video head impulse test: diagnostic accuracy in peripheral vestibulopathy*. Neurology 2009;73:1134-41.
- 12 Jorns-Häderli M, Straumann D, Palla A. *Accuracy of the bedside head impulse test in detecting vestibular hypofunction*. J Neurol Neurosurg Psychiatry 2007;78:1113-8.
- 13 Ulmer E, Chays A. *Curthoys and Halmagyi head impulse test: an analytical device*. Ann Otolaryngol Chir Cervicofac 2005;122:84-90.
- 14 Cnyrim CD, Newman-Toker D, Karch C, et al. *Bedside differentiation of vestibular neuritis from central "vestibular pseudoneuritis"*. J Neurol Neurosurg Psychiatry 2008;79:458-60.
- 15 Newman-Toker DE, Kattah JC, Alvernia JE, et al. *Normal head impulse test differentiates acute cerebellar strokes from vestibular neuritis*. Neurology 2008;70:2378-85.
- 16 Lee H, Sohn SI, Cho YW, et al. *Cerebellar infarction presenting isolated vertigo: frequency and vascular topographic patterns*. Neurology 2006;67:1178-83.
- 17 Chen L, Lee W, Chambers BR, et al. *Diagnostic accuracy of acute vestibular syndrome at the bedside in a stroke unit*. J Neurol 2011;258:855-61.
- 18 Olszewski J, Pietkiewicz P, Miłośki J, et al. *The use of VHIT in the diagnostics of semicircular canal injuries*. Otolaryngol Pol 2010;64:32-5.
- 19 Bartl K, Lehnen N, Kohlbecher S, et al. *Head impulse testing using video-oculography*. Ann N Y Acad Sci 2009;1164:331-3.
- 20 Weber KP, MacDougall HG, Halmagyi GM, et al. *Impulsive testing of semicircular-canal function using video-oculography*. Ann N Y Acad Sci 2009;1164:486-91.
- 21 Imai T, Sekine K, Hattori K, et al. *Comparing the accuracy of video-oculography and the scleral search coil system in human eye movement analysis*. Auris Nasus Larynx 2005;32:3-9.
- 22 Kidwell CS, Chalela JA, Saver JL, et al. *Comparison of MRI and CT for detection of acute intracerebral hemorrhage*. JAMA 2004;292:1823-30.

Received: May 4, 2011 - Accepted: July 13, 2011

Address for correspondence: Dr. Enrico Armato, Department of Otorhinolaryngology, ULSS 13, Hospitals of Mirano and Dolo (Venice), via Mariutto 76, 30035 Mirano (VE), Italy. Tel. +39 041 5794761. Fax: +39 041 5794799. E-mail: armato.otovest@iol.it