

CASE REPORT

# Metastasis to the right stellate ganglion and vagal nerve: pathological alterations causing sudden death. A case report

## *Morte improvvisa dovuta a metastasi del ganglio stellato di destra e del nervo vago: descrizione delle alterazioni patologiche sottostanti la morte improvvisa*

F. MAFFINI<sup>1</sup>, G. PRUNERI<sup>1,4</sup>, N. COLOMBO<sup>2</sup>, M. ANSARIN<sup>3</sup>, E. GROSSO<sup>3</sup>, R. BRUSCHINI<sup>3</sup>, L. CALABRESE<sup>3</sup>, F. CHIESA<sup>3</sup>, C. CIPOLLA<sup>2</sup>, G. PELOSI<sup>4</sup>, G. VIALE<sup>1,4</sup>

<sup>1</sup> Division of Pathology and Laboratory Medicine, European Institute of Oncology and <sup>2</sup> Cardiology Unit, European Institute of Oncology, Milan, Italy; <sup>3</sup> Division of Head and Neck Surgery, European Institute of Oncology, Milan, Italy; <sup>4</sup> University of Milan School of Medicine, Milan, Italy

### SUMMARY

Sudden death in a 66 year old woman with squamous cell carcinoma of the oral cavity and exclusive metastatic involvement of the right stellate ganglion and right nerve vagus is reported. The patient also suffered from paroxysmal atrial fibrillation treated with quinidine. An autopsy showed exclusive metastases to the right stellate ganglion and vagus nerve, along with decreased nerve fibre density in the ventricular myocardium suggesting that Wallerian axon degeneration of cardiac fibres was responsible for sudden death.

**KEY WORDS:** Sudden death • Squamous cell carcinoma • Head and neck pathology • Stellate ganglion

### RIASSUNTO

*Descriviamo un caso di morte improvvisa in una donna di 66 anni, affetta da carcinoma spinocellulare del cavo orale e con metastasi a livello del ganglio stellato di destra con coinvolgimento del nervo vago. La paziente era affetta inoltre da fibrillazione atriale parossistica (PAF) in terapia con quinidine. L'autopsia ha confermato le metastasi a livello del ganglio stellato di destra e del nervo vago omolaterale con contestuale riduzione della densità delle fibre cardiache del miocardio ventricolare, come osservato nella degenerazione Walleriana, causa della morte improvvisa.*

**PAROLE CHIAVE:** Morte improvvisa • Carcinoma spinocellulare • Patologia testa e collo • Ganglio stellato

Acta Otorhinolaryngol Ital:EPUB February 09, 2012

### Introduction

The importance of the peripheral nervous system on cardiovascular activity is well established. Cardiac sympathetic fibres originate in the upper 1 or 2 thoracic and lower 5 or 7 cervical segments, show synapses between pre- and post-ganglionic fibers mainly in the stellate or caudal cervical ganglion and have norepinephrine (NE) as a neurosecretory effector mediator. Eventually, these fibres reach the sinoatrial (SA) node, the atrio-ventricular (AV) node and the ventricular myocardial wall. In contrast, the parasympathetic system exerts opposite effects on heart activity via acetylcholine (ACh) mediation upon SA and AV node inactivation. Intramyocardial nervous fibre degeneration has been reported in different degenerative disorders such as Parkinson's disease and amyotrophic lateral sclerosis (SLA)<sup>1</sup>. Herein, we describe selective Wallerian axonal degeneration due to metastasis of carcinoma.

### Case report

In 2000, a 66-year-old-woman was hospitalized for a SCC of the gum involving the mandibular bone and concomitant paroxysmal atrial fibrillation (PAF). After chemotherapy with a ViFUP scheme (5-FU-Cisplatin-vinorelbine) and RT fractionated (72 Gy), the tumour recurred in the same site the following year. She then underwent right hemimandibulectomy with cervical lymphadenectomy for ypT4, ypN0 squamous cell carcinoma. PAF was successfully treated with quinidine (Class 1A drug, slow release, 250 mg twice a day).

In 2002, the surgical scar was removed. Despite the absence of any signs of PAF or other documented ECG abnormalities, the patient suddenly died on the second day after surgery. An autopsy was performed.

The autopsy showed signs of previous surgical procedures. A single hard white nodule measuring 1 cm in maximum

diameter was detected in the soft tissues surrounding the first right rib. Histological evaluation demonstrated that this was the right stellate ganglion (RSG). Another nodule with these characteristics, with a diameter of 2 cm, was found adjacent to the right carotid artery. The heart did not show any macroscopic alterations, and the coronary arteries and cardiac valvular system were free of atherosclerotic lesions.

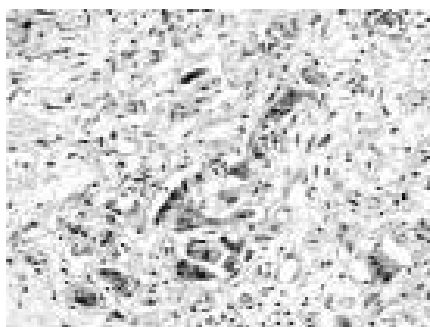
The central nervous system and other organs showed no macroscopic alterations. Samples of the midbrain, pons, bulb, heart, right carotid and RSG were histologically examined. All specimens were fixed in 4% phosphate-buffered formaldehyde for 12 hours, embedded in paraffin, cut in 4 µm sections and stained with haematoxylin and eosin. Immunohistochemistry was performed with antibodies against S-100 protein (polyclonal, dilution 1:2000, Dako) and neurofilament (NF) (2F11, dilution 1:100, Dako) by using an automated immunostainer (DakoAutostainer, Dako, Glostrup, Denmark), and then incubated with a high sensitivity detection kit (Dako EnVision Plus-HRP, Dako) according to the manufacturer's instructions. Peroxidase activity was developed with 3-3'-diaminobenzidine-copper sulphate (Sigma Chemical Co, St Louis, MO, USA) to obtain a brown-black end product.

The prevalence of nerve density in the ventricular wall was evaluated by counting all nerve fibres in 1 mm<sup>2</sup> at 400×, highlighted by the S-100 and NF antibodies on transversal sections of myocardium. The nerve density evaluated by this technique in four heart samples obtained from subjects who died of non-cardiac-related diseases were used as positive controls.

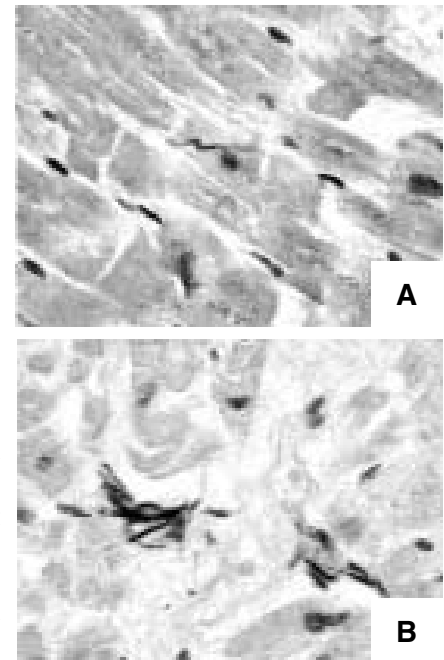
Histologically, squamous cell carcinoma was seen to permeate the perinevrium of the VN where degeneration of schwann cells and axonal bodies were observed, as well as the body of RSG where ganglion cells showed loss of Nissl's body, vacuolated cytoplasm, nuclear fragmentation and atrophy (Fig. 1).

The heart showed fragmentation of myocardium cells, without any degenerative changes of cells or band contractile degeneration.

Immunostaining for S-100 protein and NF showed a lower density nervous fibres in the ventricular wall (Fig. 2a-b).



**Fig. 1.** View of metastasis in the RSG. Neoplastic (thin arrow) and ganglion degenerate cells (thick arrow) are visible.



**Fig. 2.** Nerve density evaluated by NF staining. Pathological heart fibres (a) compared with a normal heart (b). Diminished nerve density in (a) evaluated by NF staining is apparent.

The S-100- and NF-positive mean myocardial nerve density was 340 and 2.75/mm<sup>2</sup> in the present case, respectively, and 652 and 4.6/mm<sup>2</sup> in controls, respectively. The central nervous system, as well as other organs, did not show any macroscopic or histological alterations.

## Discussion

To the best of our knowledge, this is the first report documenting a reduction of density in nervous fibres in the myocardial wall associated with metastatic involvement of RSG and VN by SCC of the oral cavity, leading to sudden death.

The role of the peripheral nervous system on cardiovascular activity is well established<sup>2</sup>. Cardiac sympathetic fibres show pre- and postganglionic synapses, mainly in the stellate or caudal cervical ganglion, and have NE as neurosecretory effectors. These fibres reach the sino-atrial (SA) node, the atrio-ventricular (AV) node and the ventricular myocardial wall. In contrast, the parasympathetic system exerts opposite effects on heart activity via acetylcholine mediation upon SA and AV node inactivation. A reduction in myocardial nervous fibres has been reported in patients affected by degenerative diseases of the cardio-regulatory centre of the brain stem and spinal cord<sup>3</sup>.

The causative mechanism responsible for disease is likely due to Wallerian axon degeneration of the RSG<sup>4</sup>, which results in progressive increases in QTc and eventual ventricular fibrillation with cardiac arrest (torsades de pointes), as documented in experimentally denervated dog hearts, chronic pain syndromes, RSG block or after neck surgery. In all these situations, the block of RSG activity is usually preceded by bradycardia and an increase in the P-P and the QTc intervals. As no specific

alterations in the QTc or P-P intervals were observed in the present case, we speculate that the disappearance of nerve fibres in the cardiac wall could evoke a Bezold-Jarish-like reflex (BJR), which leads to sudden bradycardia, ventricular fibrillation and hypotension without previous ECG alterations<sup>5</sup>.

The BJR is a cardiac reflex due to rapid enlargement of the cardiac cavity due to blood overload. Because the reflex arc is altered, it occurs incorrectly, leading to bradycardia and lowering of blood pressure, which in a heart with PAF could give rise to syncope and ventricular fibrillation.

A delayed or incomplete response of the signal can be the cause of subsequent ventricular fibrillation and sudden death even without ECG alterations, as previously demonstrated<sup>5</sup>.

The effects of the nervous system upon control of heart beat are very important, and the terminal alteration of heart nerve density should always be evaluated whenever

the cause of death is uncertain, and in particular, in patients without clinical or instrumental signs of disease.

## References

- <sup>1</sup> Orimo S, Takahashi A, Uchihara T, et al. *Degeneration of cardiac sympathetic nerve begins in the early disease process of Parkinson's disease*. Brain Pathol 2007;17:24-30.
- <sup>2</sup> Masuda A, Fujiki A, Hamada T, et al. *A transient sinus arrest after right stellate ganglion block – assessment of autonomic function by heart rate spectral analysis*. Masui 1995;44:858-61.
- <sup>3</sup> Orimo S, Kanazawa T, Nakamura A, et al. *Degeneration of cardiac sympathetic nerve can occur in multiple system atrophy*. Acta Neuropathol 2007;113:81-6.
- <sup>4</sup> Chen LS, Zhou S, Fishbein MC, et al. *New perspectives on the role of autonomic nervous system in the genesis of arrhythmias*. J Cardiovasc Electrophysiol 2007;18:123-7.
- <sup>5</sup> Mark AL. *The Bezold-Jarisch reflex revisited: clinical implications of inhibitory reflexes originating in the heart*. J Am Coll Cardiol 1983;1:90-102.

Received: March 06, 2011 - Accepted: March 20, 2011

EPUB